X-Linked Hypophosphatemia: Dental and Histologic Findings

Puneet Batra, *BDS, MDS, MOrth, RCS(Edinburgh), FFD Orth RCSI, DNB, PGDHM, PGDMLS;* ***Zahra Tejani,*** *BDS, MFDS;* ***Michael Mars,*** *DSc(Hon), PhD, BDS, FDS, DOrth*

Contact Author

Dr. Batra
Email:
pbatra87@hotmail.com

ABSTRACT

The recurrent spontaneous formation of abscesses affecting multiple noncarious primary as well as permanent teeth is the principle clinical dental feature in cases of hypophosphatemia, a condition inherited through the X chromosome. Patients often have high pulp horns, large pulp chambers and dentinal clefts. We report a case of hypophosphatemic vitamin D-resistant rickets in a patient who reported to our department on multiple occasions with spontaneous abscesses in relation to his primary teeth. The aim of this article is to review the features of this disorder and to discuss the risks and benefits of the treatment options suggested in the literature.

MeSH Key Words: abscess/physiopathology; child; dental pulp diseases; hypophosphatemia/physiopathology

© *J Can Dent Assoc* 2006; 72(1):69–72
This article has been peer reviewed.

Hypophosphatemic vitamin D-resistant rickets or X-linked hypophosphatemia is associated with well documented oral and dental findings.[1–6] Recurrent spontaneous abscess formation affecting multiple noncarious primary teeth is the principle clinical feature in these cases. Similar episodes have been reported in the permanent dentition. Dentists have diagnosed a few cases in which the systemic features were mild and dental abscesses were the first presenting sign.[3] Hypophosphatemic rickets often features high pulp horns, large pulp chambers and dentinal clefts.[5,6] It is believed that the abscesses form when pulp is infected by bacteria invading through the enamel cracks and dentinal microcleavages in the teeth.[7,8] Usually both primary and permanent teeth have dentinal dysplasia.[5] The teeth usually show taurodontism, poorly defined lamina dura and a hypoplastic alveolar ridge.[8,9]

Case Report

A 3-year-old boy with X-linked vitamin D-resistant hypophosphatemia was referred to the maxillofacial and dental department at Great Ormond Street Hospital for Children for a dental evaluation. General physical examination revealed typical bowing of the legs, marked genu valgum and rachitic rosary. Genu valgum or "knock-knee" deformity results in circumduction, a gait that requires the individual to swing each leg outward while walking to avoid striking the planted limb with the moving limb. Rachitic rosary is the name given to the bead-like enlargements of the costochondral junctions.

There was a history of rickets on the maternal side of the family (**Fig. 1**). The patient had a marked anterior open bite associated with the use of a pacifier. In the past, his serum calcium level was 1.1 mg/dL, phosphate level was 0.94 mg/dL and alkaline phosphatase was elevated (367 mU/mL). He had been treated with 125 mg of sodium acid phosphate and 40 mg/kg of 1,25-dihydroxy vitamin D daily. General oral hygiene instructions were given and pacifier use was discouraged.

However, between the ages of 4 and 10 years, the boy presented at regular intervals with spontaneous abscesses (**Table 1**). In each case, the tooth was sound, caries-free and had no

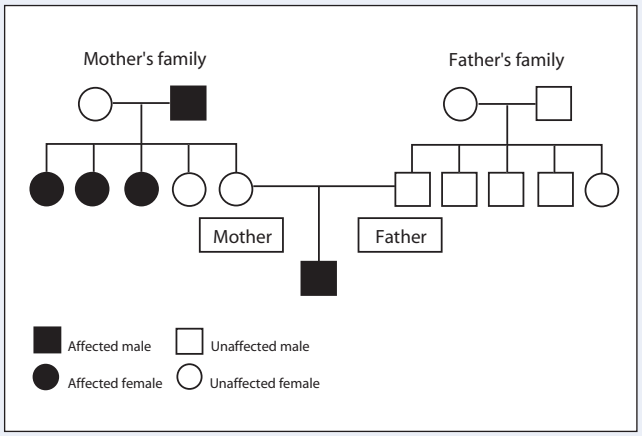

Figure 1: Pedigree chart showing the transmission of rickets from the maternal side: mother and father are phenotypically unaffected by the condition but are carriers of the affected gene.

Figure 2: Orthopantomograph shows the remaining deciduous molars with stainless steel crowns and the lower canine in the midline associated with a cystic swelling.

Table 1 Occurrence of spontaneous abscesses in the patient between the ages of 4 and 10 years

Age at time of presentation (years and months)	Tooth involved	Diagnosis at presentation
4.7	61	Acute periapical abscess
5.3	64	Chronic periapical sinus
5.4	52	Palatal abscess
6.4	71, 54	Acute periapical abscesses
7.6	74	Acute periapical abscess
7.7	53	Acute periapical abscess
8.2	84	Acute periapical abscess
9.11	63, 83	Acute periapical abscess

history of trauma. The boy often displayed submandibular lymphadenopathy associated with the abscesses. There was radiographic evidence of spontaneous root resorption in tooth 64. The teeth listed in **Table 1** were extracted under local anesthetic to prevent further abscess formation. Preventive stainless steel crowns were placed on all second deciduous molars. The permanent molars presented with deep fissures warranting the placement of preventive sealants.

At the age of 11 years, the boy presented with an asymptomatic unerupted tooth 33 and a firmly retained tooth 83. On clinical examination, a hard, painless swelling and slight expansion of the labial cortical bone could be palpated in the region of tooth 41. All lower teeth were responsive to ethyl chloride and sound, and there were no changes in axial position. Radiographs confirmed that the lower left canine had transmigrated from the left side of the mandible toward the right and was closely associated with the roots of teeth 31, 41 and 42. The canine was associated with a cyst-like lesion extending from the root of tooth 42 to the mesial aspect of the root of 34; its diameter was approximately 20 mm. The first permanent molars showed evidence of quadrangular taurodontism (**Fig. 2**).

As the canine was severely malpositioned, exposure and transplantation or orthodontic movement of the tooth into its correct position would have been unsuccessful. Surgical extraction of tooth 33 and enucleation of the associated cystic lesion were deemed necessary to prevent damage to the adjacent teeth from potential further expansion of the cyst. The procedure was carried out under general anesthetic. The histopathological report identified the lesion as a follicular or dentigerous cyst.

The patient is under regular review with the aim of providing orthodontic treatment for him in the future.

Discussion

Hypophosphatemic rickets is associated with defective resorption of phosphate in the proximal renal tubule and inadequate synthesis of 1,25-dihydroxy vitamin D from its precursor 25-hydroxy vitamin D.[9–11] Its prevalence is approximately 1 in 20 000. Of interest from the developmental perspective is the presence of taurodontism in the first and second permanent molars in many male patients (males are more severely affected by this X-chromosome linked dominant condition).[12,13] Reports show a similar relation between this disorder and ectopically placed permanent canines. Hypophosphatemic rickets will usually manifest in 50% of the male children of a woman who is a carrier. It is inherited by a female when the disease manifests in the father and the mother is the carrier of the trait.

Histologically, teeth have enlarged pulp chambers, wide predentin, marked globular dentin and tubular dentinal defects extending from the pulp to the enamel. Enamel hypoplasia may or may not be present.[14,15] Abe and others[16] have suggested that the globular dentin caused by hypophosphatemia impairs calcification. The incompletely mineralized dentin exists in the form of calcospherites, which trap microorganisms and also impede mechanical endodontic cleaning. In addition, the thin dentin layer perforates easily and does not support restorative posts for prosthetic crowns. According to Hillmann and Geurtsen,[17] the permanent teeth might also be affected and histopathologic examination of the permanent dentition is necessary. Usually the younger the patient is when the first abscess appears, the more severe the dental manifestation.[14]

Although odontoblast function is normal, hypophosphatemia leads to dysplastic and poorly mineralized dentin with areas of interglobular dentin. Because enamel and dentin formation occur between 4 months in utero and 11 months of age, the defects in the primary dentition can usually not be prevented. However, permanent teeth form after birth and their development could possibly be improved by medication started soon after birth. Abnormal dental development and dentin formation may persist despite therapy. The sequence of formation of abscesses usually appears to follow the sequence of eruption.[12,17]

Some authors advocate extraction of teeth that present periradicular abscesses and eventual restoration with implants; however, endodontic and restorative treatment may not be able to maintain asepsis.[18,19] One must conclude that the occurrence of spontaneous abscesses following a shallow cavity preparation necessitates aggressive preventive dental procedures.[20] In patients with this disorder, professional dental care consisting of periodic examinations, topical fluoride applications and maintenance of good oral hygiene is imperative.[21] Moreover, the dentist as well as the pediatrician should be made aware of the features of this disorder so that early intervention can prevent subsequent serious and more invasive dental procedures. Prophylactic coverage of these teeth with stainless steel crowns on molars and composite resin on the anterior teeth should be done. This treatment should be carried out with caution and crown preparation should be minimal to avoid inadvertent pulp exposure. Another critical factor is the loss of vertical dimensions if multiple posterior primary teeth need to be extracted. Thus, there is a delicate balance between the benefits and possible risks of using stainless steel crowns. Pit and fissure sealants are useful when the teeth are erupting as they prevent ingress of bacteria into the enamel microfractures as well as initiation of caries in the deep pits and fissures.

It is evident that although permanent teeth form after birth and their development could possibly be affected by medication started soon after birth, abnormal dental development and dentin formation may persist despite therapy. However, early diagnosis and medication may be useful in many cases. Controversy exists regarding the management of these cases with extraction of teeth at presentation of abscess, the questionable success of endodontic treatment and the possible benefits and risks associated with the use of stainless steel crowns. However, dental care of these patients should consist of periodic examinations, topical fluoride applications, pit and fissure sealants and maintenance of good oral hygiene.

THE AUTHORS

Dr. Batra is a reader in orthodontics at the Institute of Dental Studies and Technologies, Delhi, India.

Dr. Tejani is a post-graduate student in orthodontics at the Eastman Dental School in London, England.

Dr. Mars is lead consultant orthodontist, North Thames cleft lip and palate service, maxillofacial and dental department, Great Ormond Street Hospital for Children NHS Trust.

Correspondence to: Dr. Puneet Batra, Institute of Dental Studies and Technologies, Delhi-Meerut Road, NH-58, Kadrabad, National Capital Territory, Delhi, Modinagar-201201, India.

The authors have no declared financial interests.

References

1. Berndt M, Ehrich JH, Lazovic D, Zimmermann J, Hillmann G, Kayser C, and others. Clinical course of hypophosphatemic rickets in 23 adults. *Clin Nephrol* 1996; 45(1):33–41.

2. Gallo LG, Morle SG. Spontaneous dental abscess in vitamin-D-resistant rickets: report of a case. *J Dent Child* 1979; 46(4):327–9.

3. Yamazaki H, Otake Y, Tomizawa M, Noda T, Suzuki M. [A case of hypophosphatemic vitamin D-resistant rickets in which spontaneous dental abcesses were the first evidence.] *Shoni Shikagaku Zasshi* 1985; 23(1):204–14. Japanese.

4. Goodman JR, Gelbier MJ, Bennett JH, Winter GB. Dental problems associated with hypophosphataemic vitamin D resistant rickets. *Int J Pediatr Dent* 1998; 8(1):19–28.

5. Murayama T, Iwatsubo R, Akiyama S, Amano A, Morisaki I. Familial hypophosphatemic vitamin D-resistant rickets: dental findings and histology study of teeth. *Oral Surg Oral Med Oral Pathol Oral Radiol Endod* 2000; 90(3):310–6.

6. Seow WK. X-linked hypophosphatemic vitamin D-resistant rickets. *Aust Dent J* 1984; 29(6):371–7.

7. McWhorter AG, Seale NS. Prevalence of dental abscess in a population of children with vitamin D-resistant rickets. *Pediatr Dent* 1991; 13(2):91–6.

8. Yasufuku Y, Kohno N, Tsutsumi N, Ooshima T, Sobue S, Murakami Y, and other. Dental management of familial hypophosphatemic vitamin D-resistant rickets: report of case. *ASDC J Dent Child* 1983; 50(4):300–4.

9. Bender IB, Naidorf IJ. Dental observations in vitamin D-resistant rickets with special reference to periapical lesions. *J Endod* 1985; 11(11):514–20.

10. Breen GH. Prophylactic dental treatment for a patient with vitamin D-resistant rickets: report of a case. *ASDC J Dent Child* 1986; 53(1):38–43.

11. Rakocz M, Keating J 3rd, Johnson R. Management of the primary dentition in vitamin D resistant rickets. *Oral Surg Oral Med Oral Pathol* 1982; 54(2):166–71.

12. Seow WK, Latham SC. The spectrum of dental manifestations in vitamin D-resistant rickets: implications for management. *Pediatr Dent* 1986; 8(2):245–50.

13. Vasilakis GJ, Nygaard VK, DiPalma DM. Vitamin D resistant rickets. A review and case report of an adolescent boy with a history of dental problems. *J Oral Med* 1980; 35(1):19–26.

14. Seow WK, Romanink K, Sclavos S. Micromorphologic features of dentin in vitamin D-resistant rickets: correlation with clinical grading of severity. *Pediatr Dent* 1989; 11(3):203–8.

15. Seeto E, Seow WK. Scanning electron microscopic analysis of dentin in vitamin D-resistant rickets: assessment of mineralization and correlation with clinical findings. *Pediatr Dent* 1991; 13(1):43–8.

16. Abe K, Ooshima T, Lily TS, Yasufuku Y, Sobue S. Structural deformities of deciduous teeth in patients with hypophosphatemic vitamin-D resistant rickets. *Oral Surg Oral Med Oral Pathol* 1988; 65(2):191–8.

17. Hillmann G, Geurtsen W. Pathohistology of undecalcified primary teeth in vitamin D-resistant rickets: review and a report of two cases. *Oral Surg Oral Med Oral Pathol Oral Radiol Endod* 1996; 82(2):218–24.

18. Pereira CM, de Andrade CR, Vargas PA, Coletta RD, de Almeida OP, Lopes MA. Dental alterations associated with X-linked hypophosphatemic rickets. *J Endod* 2004; 30(4):241–5.

19. Tulloch EN, Andrews FF. The association of dental abcesses with vitamin D resistant rickets. *Br Dent J* 1983; 154(5):136–8.

20. Herbert FL. Hereditary hypophosphatemia rickets: an important awareness for dentists. *ASDC J Dent Child* 1986; 53(3):223–6.

21. Cohen S, Becker GL. Origin, diagnosis, and treatment of the dental manifestations of vitamin D-resistant rickets: a review of the literature and report of a case. *J Am Dent Assoc* 1976; 92(1):120–9.